

Canine left ventricular mass estimation by two-dimensional echocardiography

NELSON B. SCHILLER, M.D., CLAES G. SKIÖLDEBRAND, M.D., ELLEN J. SCHILLER, B.S.,
CONSTANTINE C. MAVROUDIS, M.D., NORMAN H. SILVERMAN, M.D., SHAHBUDIN H. RAHIMTOOLA, M.D.,*
AND MARTIN J. LIPTON, M.D.

ABSTRACT This study was designed to develop a two-dimensional echocardiographic method of measuring the mass of the left ventricle. The general formula for an ellipse was used to derive an algorithm that described the shell volume of concentric truncated ellipsoids. In 10 canine left ventricular two-dimensional echocardiograms, this algorithm accurately predicted postmortem left ventricular mass ($r = .98$, SEE ± 6 g) and was independent of cardiac cycle phase (systole vs diastole, $r = .92$). *Circulation* 68, No. 1, 210-216, 1983.

LEFT VENTRICULAR MASS is an important descriptor of cardiac functional status. Pathologically or physiologically increased mass results from the hypertrophic process that frequently, but not always, is accompanied by increased wall thickness. Invasive and noninvasive imaging techniques such as M mode echocardiography and angiography allow quantitation of left ventricular mass by methods that rely on limited measurements of wall thickness taken from one or two loci at the cardiac base in combination with ventricular volume estimates of varying accuracy.¹⁻⁷

Although M mode methods have been shown to have useful clinical and investigative applications,⁷⁻⁹ they require technically excellent septal and posterior wall imaging and are proscribed in regional myocardial disease.⁶ Two-dimensional echocardiography has been shown to provide noninvasive cardiac images from which left ventricular volumes can be reliably measured.¹⁰⁻¹² These methods are superior to M mode

methods regardless of geometry¹³ and many retain their accuracy in segmental disease.^{10, 11, 14} A geometrically rational method of measuring mass from two-dimensional echocardiograms is desirable because it should be less vulnerable to errors arising from the extrapolation of three-dimensional information from linear measurements and from segmental disease.

Our purpose was to develop and validate a two-dimensional echocardiographic technique for estimating left ventricular mass in which a geometrically representative algorithm, a representative measure of wall thickness, and easily obtained internal left ventricular dimensions are used.

Methods

The study consisted of two phases. In the first phase an algorithm was derived that was both anatomically logical and solvable with easily obtained echocardiographic dimensions; in the second phase this algorithm was tested in an animal model.

Derivation of a mass algorithm. A truncated ellipsoid of revolution was used as a model for developing the algorithm because its shape closely resembles that of the left ventricle. Geiser and Bove¹⁵ found that a similar model provided accurate left ventricular mass predictions from direct measurements of postmortem ventricular wall thickness. Figure 1 is a schematic representation of the long- and short-axis sections of the left ventricle as a truncated ellipsoid. This figure shows the locations of some of the minor-axis radii (semiminor axis) and the major- or long-axis segments (semimajor axis and truncated semimajor axis).

Wall thickness was approximated from the short axis at the level of the papillary muscle tips by directly tracing and measuring the areas bounded by the epicardium and endocardium. As figure 2 illustrates, each area is treated as a circle, the radius (r) of which can be calculated from the relationship $A = \pi r^2$. The difference between radii is an estimate of wall thickness representative of the minor axis. In view of the inherent limitations of

From the Departments of Medicine (Cardiovascular Division), Radiology, Pediatrics, and Surgery and the Cardiovascular Research Institute of the University of California, San Francisco.

Address for correspondence: Nelson B. Schiller, M.D., University of California, San Francisco, 521 Parnassus Ave., Room C-340, San Francisco, CA 94143.

Received July 23, 1982; revision accepted March 10, 1983.

Dr. Schiller was supported in part by NHLBI Young Investigators Research Grant R23HL22787 and by NHLBI grant RO1AM28121.

Dr. Skiöldbrand was supported by the Swedish American Foundation, Stockholm.

Dr. Silverman is a recipient of a grant from the California Heart Association.

Dr. Lipton is the recipient of a USPHS Research Career Development Award (5K04 HL00360) from the NHLBI, Bethesda.

*Present address: Section of Cardiology, University of Southern California, Los Angeles.

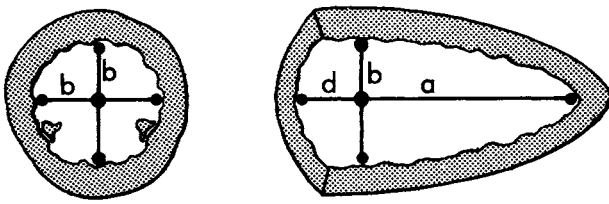


FIGURE 1. Diagrammatic representation of the left ventricle as a truncated ellipsoid. In the short axis (*left*) and the long axis (*right*) the internal dimensions used in this study are shown. Four semiminor axes or radii (*b*) are shown in the short axis and two are shown in the long. Note that the placement of the minor diameter (equivalent to two semiminor axes) determines the division of the semimajor axes. The full semimajor axis (*a*) and the truncate semimajor axis (*d*) appear in the long-axis representation of the left ventricle.

two-dimensional visualization of the epicardial surface, this estimation of wall thickness is the only operation in our method of mass determination in which the epicardial surface of the left ventricle is used. This method makes no attempt to account for apical wall thinning.

Figure 3 shows the superimposition of the Cartesian coordinate system on a model of the left ventricle; this facilitates the derivation of an algorithm based on a truncated ellipsoid.

The formula for the volume of the shell of a truncated ellipsoid and its derivation are shown in figure 4. This formula was obtained by integration of the general equation of an ellipse by the method of concentric discs. The left side of the bracketed expression gives the volume of the outer shell of the left ventricle and the right side gives that of the inner shell. Left ventricular myocardial mass is the difference between the volumes of these shells multiplied by myocardial density (1.05 g/ml).

Solution of this equation requires the following four echocardiographically available variables: (1) mean wall thickness, (2) radius of the semiminor axis of the left ventricular cavity, (3) length of the semimajor axis of the cavity, and (4) the length of the truncated semimajor axis of the cavity.

Experimental validation of the algorithm. The algorithm for left ventricular mass, derived from a truncated ellipsoid, was tested by the use of 10 litter-matched beagle pups. Five of these animals underwent surgery when they were 6 to 8 weeks old. The ascending aorta was exposed and a coarctation was created by banding it with umbilical tape 1 to 2 cm above the aortic valve. The purpose of this coarctation was to raise ventricular afterload and thus stimulate various degrees of hypertrophy. The aortic circumference was reduced 25% to 45% to produce an intraoperative thrill. All animals that were operated on continued to have both bruits and thrills after surgery. These dogs were then raised with their five normal litter mates. Echocardiography was performed in dogs that were between 7 and 9 months old, after the animals had been anesthetized by a combination of xylazine and ketamine hydrochloride. During the echocardiogram ventilation was maintained by a cuffed endotracheal tube. In all cases it was possible to manipulate pulmonary inflation so that an optimal transthoracic echocardiographic image could be recorded. Immediately after echocardiography the animals were killed pharmacologically. After removal of the right ventricle, the atria, and the valves from the hearts of these dogs, the isolated left ventricles were weighed. These weights were recorded by one of the investigators who was not involved in the generation or interpretation of the echocardiograms and the weights were not made available until the echocardiographic examinations and calculations were completed.

All echocardiograms were recorded with a wide-angle phased-array instrument (Varian Associates Model V-3000) by

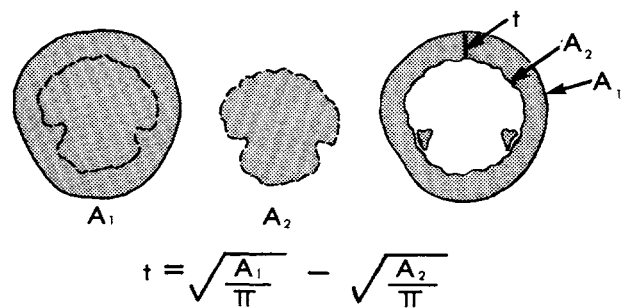


FIGURE 2. Computation of a representative wall thickness (*t*) with the use of the short axis of the left ventricle at the level of the tips of the papillary muscles. In this method planimetry provides the area enclosed by the epicardium (A_1). Planimetric measurement of the endocardium (A_2) describes the area of the cavity in this plane. If one assumes that the computed areas are those of a circle, then the radius of each circle can be computed. The difference between these radii is an expression of left ventricular wall thickness at the level of the papillary muscle tips.

the method of Wyatt et al.¹⁶ In this method animals are positioned on their right sides so that the cardiac impulse can be used as an imaging window. We used a specially constructed plastic table into which several large holes had been drilled. The cardiac impulse was positioned over one of the holes through which the transducer could be passed from beneath (figure 5). In each dog a short-axis echogram at the papillary muscle tips and a long-axis echogram from an orthogonal transducer location were recorded simultaneously with a surface electrocardiogram. Figure 6 shows the echograms from these two views in a normal and a banded dog. Gain settings and gray levels were optimized to enable imaging of both epicardial and endocardial surfaces. In all cases the maximum long-axis dimension was sought. At times it was difficult to keep the tip of the left ventricular apex in the field of view throughout the cardiac cycle, but the apex tip was always seen intermittently during real-time playback of the recorded images. We were able to obtain images of good quality in all dogs; figure 6 is representative of these.

Quantitative analysis of the echograms was performed by the method illustrated in figures 7 and 8. A commercially available, preprogrammed, microcomputer-controlled, light-pen digitizing system (Diasonics) was used to make measurements from stop-frame videotape replay. We analyzed stop-frame images at the end of passive filling with the use of the onset of the electro-

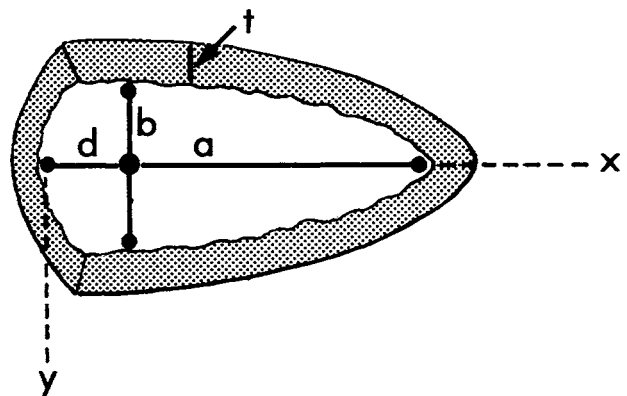


FIGURE 3. Placement of the diagrammatic representation of the left ventricle as a truncated ellipsoid along the Cartesian coordinates. Labels are as in figures 1 and 2.

$$V = \pi \left\{ (b+t)^2 \int_0^{d+a+t} \left[1 - \frac{(x-d)^2}{(a+t)^2} \right] dx - b^2 \int_0^{d+a} \left[1 - \frac{(x-d)^2}{a^2} \right] dx \right\} =$$

$$\pi \left\{ (b+t)^2 \left[\frac{2}{3}(a+t) + d - \frac{d^3}{3(a+t)^2} \right] - b^2 \left[\frac{2}{3}a + d - \frac{d^3}{3a^2} \right] \right\}$$

MASS = 1.05 V

FIGURE 4. The equation resulting from the use of the general equation for an ellipse and the method of concentric cylindrical discs. Essentially, this equation computes the volume of the myocardium by calculating the volume enclosed within the outer shell of the left ventricle and subtracting from that value ventricular cavity volume. The *a*, *b*, *d*, and *t* in the equation correspond to the labels in figures 1 and 2.

cardiogram P wave as a marker of this portion of the cardiac cycle. In tracing endocardial and epicardial outlines we used the light-pen system to superimpose a line on these structures. The short-axis endocardium was traced by covering the innermost edge of that surface with a light pen-generated line. The epicardium was traced by placing the line atop the first bright area immediately outside the relatively echo-free myocardium. Placement of this line was also guided by noting the location of the slight systolic separation between the layers of the pericardium, which was usually seen during real-time viewing. In long-axis images, the placement of the minor axis defined the length of the semimajor axis and the truncated semimajor axis. The placement of the minor-axis plane was chosen after real-time images were viewed and the location of the papillary muscle tip/chordal junction was estimated. This junction was chosen as the location of the minor axis.

Two individuals performed independent echocardiographic measurements so that interobserver variation could be established. In addition, one of these observers repeated his measurements to establish intraobserver variability. Finally, one of the observers performed measurements at end-systole to determine whether there was any significant influence of cardiac cycle phase on these mass measurements. In all cases each computation consisted of three sets of measurements in each animal. In each of these measurement sets three minor-axis determinations were averaged (two from the short axis and one from the long) to obtain a representative value of the minor-axis radius. Because of the lengthy nature of the calculations required for our formula, we programmed a desk-top card-programmable calculator to perform this computation (Texas Instruments TI-59).

Results

Experimental validation of algorithm. The measurements obtained with the echocardiograms of 10 dogs were correlated with postmortem left ventricular weight (figure 9). All numbers were reported to the nearest gram. The mean postmortem weight of the 10 canine left ventricles was 87 ± 31 g and the mean echocardiographic weight was 78 ± 26 g. The individual heart weights by each method were then compared by linear regression analysis. The relationship between the echographically calculated weight and the actual weight was given by the equation left ventricular mass (echo) = 0.9 postmortem weight + 4.2 ($r = .98$, SEE ± 6 g).

Interobserver variation was 12% ($r = .95$) and intraobserver variation was 9% ($r = .98$). When echocardiographic measurements were made at end-systole the mean echocardiographic mass for the 10 dogs was 81 ± 24 g; the correlation coefficient for the comparison of the systolic and diastolic values was .92.

Discussion

Increased mass or weight of the left ventricle is one of the anatomic features that frequently separates the normal from the morbid; its longstanding use in gross pathology attests to its usefulness. Mass, unlike wall thickness and cavity volume, is constant throughout the cardiac cycle. A reasonably accurate method of determining mass from two-dimensional echocardiograms is of considerable potential value in that it would provide clinically relevant information that previously could not be obtained by noninvasive means.

We have developed a method of echocardiographically estimating left ventricular mass in which a new algorithm, solved with variables that are easily mea-

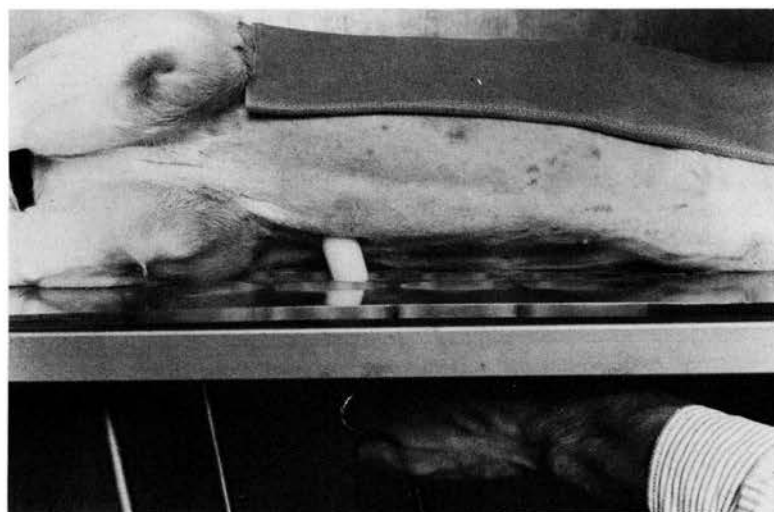


FIGURE 5. The heart of the dog can be imaged echographically from either the right or left chest. With the dog on its right side the cardiac impulse becomes palpable and provides a window for imaging. To make this window accessible, a table with large holes drilled into it was used. Positioning the cardiac impulse over one of these holes and passing the phased-array transducer underneath the table through this hole and onto the chest wall of the animal permitted rapid acquisition of high-quality images in all of the animals studied.

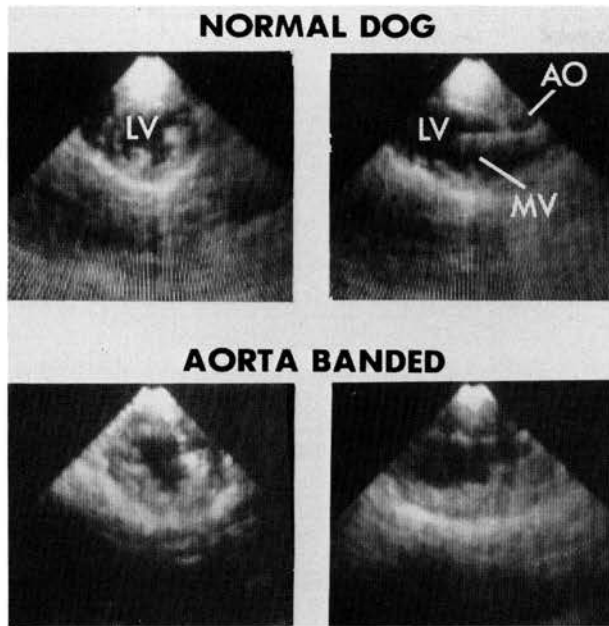


FIGURE 6. Echograms obtained in the short and long axes (the two views used in our study) from a normal and a banded dog. There were considerable differences in appearance between the normal dogs and those who had undergone aortic banding. AO = aorta; LV = left ventricle; MV = mitral valve.

sured on a two-dimensional echocardiogram, is used. This algorithm assumes that the left ventricle is shaped like a truncated ellipsoid, an assumption that conforms to its anatomic appearance. We also used a technique for estimating wall thickness that avoids errors inherent in methods in which one or two local samples are

used. Our method, in which the short-axis view of the left ventricle is used, takes advantage of its nearly circular shape and of its good representation of endocardium and epicardium and, since wall thickness is derived from the areas subtended by the epicardium and endocardium, errors that arise from surface irregularities or even asymmetric wall thickness are minimized. With the exception of the calculation of wall thickness from the area enclosed by the epicardium, our method of mass determination is based entirely on internal measurements. The results of our canine studies are similar to those of Wyatt et al.¹⁵ and suggest that this method is sufficiently accurate for clinical trials because it predicts left ventricular mass through a wide range of values with a low SEE.

Evaluation of interobserver and intraobserver variation shows that in this respect our method is comparable to other two-dimensional quantitative echographic techniques and that the variation is well within limits from all imaging methods. However, in this study we did not test the reliability or accuracy of this method in detecting small serial changes.

Our formula describing the volume of a truncated ellipsoid of revolution requires only relatively simple measurements from the echocardiogram. The calculations involved are tedious to perform, however, and some form of programmable computer is required. The formula of Wyatt et al.¹⁵ is based on a similar mathematic model and produced similar results in the dog model while demanding less complex mathematic ma-

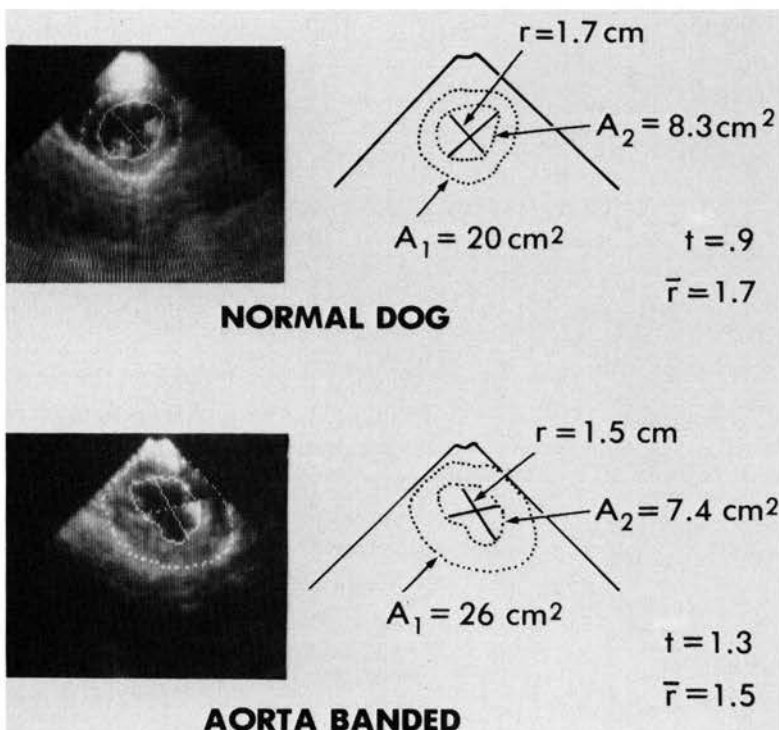


FIGURE 7. *Left*, The short-axis echocardiograms from a normal and a banded dog. Superimposed on these echocardiograms are the light-pen microprocessor-generated outlines that are manually traced during the process of computation. Note that the endocardial tracings just cover the inner edge of the endocardium. *Right*, The values obtained from the microprocessor system for each animal. Note the difference between the values obtained from the normal animal and those from the hypertrophic animal. r = radius; all other labels are as in figures 1 and 2.

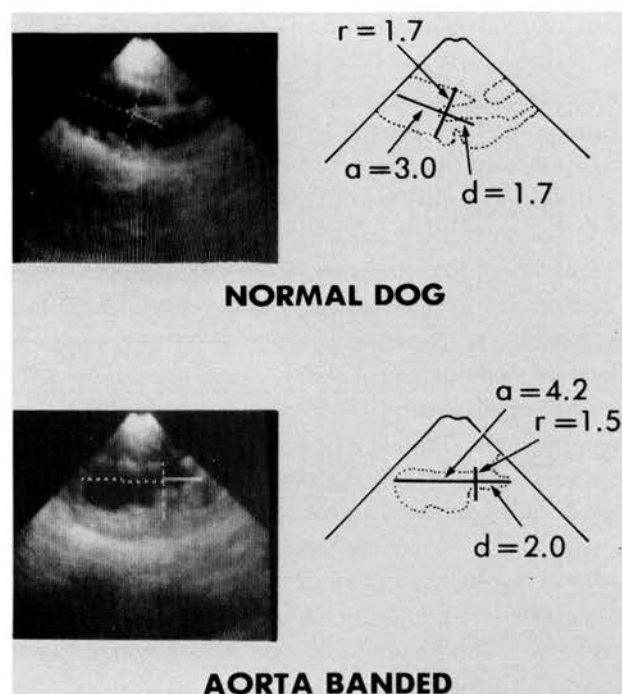


FIGURE 8. Left, A reproduction, with superimposed computed tracings, of the long-axis echograms of the dogs in figure 7. Right, A diagrammatic representation of the echograms. In the long axis internal dimensions only were measured. r = radius; all other labels are as in figure 1.

nipulation. However, since the Wyatt formula was derived by obtaining the simple arithmetic average of the area-length formula of an ellipse and the area-length formula of a cylinder, the minor axis of this geometric model lies at the midpoint of its major axis and the application of this algorithm to an image of the left ventricle presumes that the minor axis will be similarly placed. In the left ventricle the minor axis is not

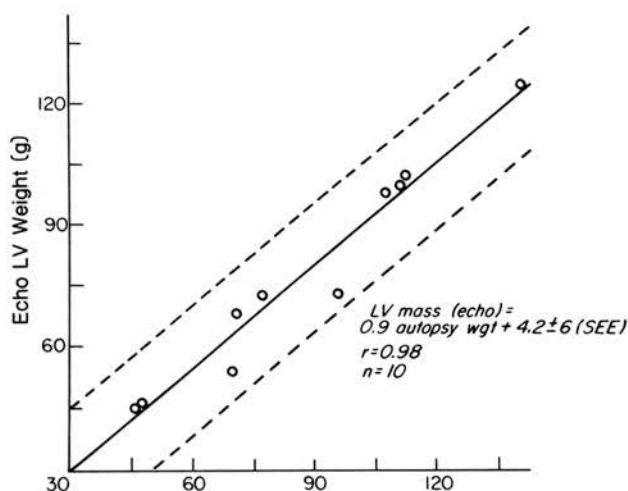


FIGURE 9. The autopsy weights of the left ventricles of the 10 animals in our study plotted against the computed echocardiographic left ventricle weights for the animals.

centered, but is distinctly basal to the midpoint of the major axis. This discrepancy between the Wyatt model and the left ventricle could introduce error. In our formula, placement of the minor axis can conform to its actual position in the ventricle without compromising the model or introducing error; it is thus a more accurate mathematic representation of the structure.

Like Henry *et al.*,¹⁷ we have chosen to make our measurements in the portion of diastole just before atrial contraction; the heart moves very little at this point in the cycle, allowing optimal visualization of cardiac surfaces, and we believe that this method produces the most meaningful measurement of wall thickness. When wall thickness is examined before atrial contraction a sample of the wall after passive filling is obtained. The approach becomes important in hypertrophy in which the relative contribution of passive filling to total filling has decreased and that of atrial filling has increased. Our own observation of M mode echocardiograms show that the wall of a hypertrophic ventricle can be stretched to near "normal" thickness by a powerful atrial contraction, in spite of an abnormally increased measurement just before atrial systole. Diastolic measurement also facilitates separation of papillary muscles and trabeculae from the mural endocardium. Superimposition of local irregularities on the mural endocardium is probably a major factor contributing to the larger SEE that we obtained from measurements made at end-systole.

Although we believe that wall thickness measurements made just before atrial contraction are the most informative, wall thickness is not always a satisfactory parameter for evaluating left ventricular mass.⁹ For example, in hemodynamically important pericardial effusion left ventricular wall thickness can be seen to increase as an obligatory result of a hypovolemic decrease in cavity size. A measurement of left ventricular mass in this situation will produce a normal value. Conversely, in dilated hearts hypertrophy may be severe but masked by obligatory thinning of the left ventricular wall.

Mass remains nearly constant throughout the cardiac cycle. Therefore, a test of any method is to use it in mass computations performed at two or more points in the cycle. In this study we compared our standard late-diastolic computation with one at end-systole. There was close correlation between results of the two examinations ($r = .92$). When a similar test was performed with standard M mode methods, we found systolic mass estimations to exceed diastolic values by at least 40%. For example, if the method of Troy *et al.*⁵ is applied to a published normal M mode echocardi-

gram (figure 1 in Ditchey et al.⁸), the value for diastole is 200 g and for systole, 276 g. If the Penn convention⁶ is applied to the same echocardiogram the value for diastole is 101 g and for systole, 156 g. While the finding of discrepant values does not negate the usefulness of these methods it supports the rationale for developing two-dimensional methods that are based on more secure geometric assumptions.

Although our method of mass determination is accurate in dogs, in patients results of early clinical trials in which angiography was used as a reference standard were inconclusive.¹⁸ An in vitro study of sliced human ventricles¹⁹ suggested that two-dimensional echocardiography can accurately measure wall volume. However, prominent cavitory trabeculations, which in the contracted fixed specimen obscured the location of the endocardium, led to the overestimation of myocardial volume.

Recently we calculated left ventricle mass from two-dimensional echocardiograms of 52 normal subjects.²⁰ There was a significant difference between the sexes ($p < .0001$); the mean mass for male subjects ($n = 29$) was 135 g and for female subjects ($n = 23$), 99 g. In an older postmortem population of 45 subjects with "normal" hearts, Reiner et al.²¹ found mean values of 155 g for men and 115 g for women. Since age was found to significantly increase left ventricle mass and since our population was younger than their's (mean 38 vs 55 years), we consider the results of this study to be in close agreement with ours and view this agreement as indirect evidence of the validity and potential clinical applicability of our approach.

Compared with values from the postmortem study of Reiner et al.,²¹ normal values obtained angiographically differed from those determined echocardiographically in that angiography tended to overestimate anatomic weights. For example, Kennedy et al.²² found a mean angiographic left ventricular mass of 188 ± 33 g in 15 normal men (mean age 44 years) and a mass of 121 ± 14 g in seven normal young women (mean age 23 years). The relationship of angiographic to echocardiographic data that is implied by comparison with normal values is, as might be expected, that echocardiography underestimates and angiography overestimates left ventricular mass. Final evaluation of the accuracy of echocardiography will, however, necessitate direct comparisons between in vivo echocardiograms and postmortem weights.

In summary, we have developed an algorithm for noninvasively measuring the mass of the left ventricle. Geometrically, this method is based on the formula for a truncated ellipsoid, a model more representative of

the heart than an ellipsoid. This study has shown this method to be accurate in both normal and hypertrophied canine hearts and during two phases of the cardiac cycle.

Addendum

Since submission of this manuscript, Reichek et al.²³ have published the results of a study that compared left ventricular mass derived from two-dimensional images with postmortem weights in terminally ill patients. Their findings indicate that the two-dimensional method is superior to M mode methods ($r = .93$ vs $.86$ and $SEE = 31$ vs 59 g). The algorithm they used¹⁶ was derived from similar but less fastidious geometric assumptions than those used in our study, but their mass estimates remained accurate in the face of prevalent geometric distortions. We view the results of the report of Reichek et al.²³ as further evidence supporting the validity and potential clinical applicability of two-dimensional echocardiographic methods of estimating left ventricular mass.

References

1. Rackley E, Dodge T, Coble YD, Hay E: A method of determining left ventricular mass in man. *Circulation* **29**: 666, 1964
2. Kennedy J, Reichenbach D, Baxley A, Dodge HT: Left ventricular mass — a comparison of angiocardiographic measurements with autopsy weight. *Am J Cardiol* **19**: 221, 1967
3. Kennedy JW, Trenholme SE, Kasser I: Left ventricular volume and mass from single-plane cineangiogram. A comparison of anteroposterior and right anterior oblique methods. *Am Heart J* **80**: 3, 1970
4. Jaffe C, Kent E: Roentgenographic quantitation of left ventricular volume and muscle mass. *Curr Probl Radiol*, Jan-Feb, 4-55, 1974
5. Troy L, Pombo J, Rackley C: Measurement of left ventricular wall thickness and mass by echocardiography. *Circulation* **45**: 602, 1972
6. Devereux R, Reichek N: Echocardiographic determination of left ventricular mass in man — anatomic validation of the method. *Circulation* **55**: 613, 1977
7. Reichek N, Devereux R: Left ventricular hypertrophy: relationship of anatomic echocardiographic and electrocardiographic findings. *Circulation* **63**: 1391, 1981
8. McFarland TM, Mohsin A, Goldstein S, Pickard SD, Stein PD: Echocardiographic diagnosis of left ventricular hypertrophy. *Circulation* **57**: 1140, 1978
9. Ditchey RV, Schular G, Peterson K: Reliability of echocardiographic and electrocardiographic parameters in assessing serial changes in left ventricular mass. *Am J Med* **70**: 1042, 1981
10. Schiller NB, Acquatella H, Ports TA, Drew D, Goerke J, Ringertz H, Silverman NH, Brundage B, Botvinick EH, Boswell R, Carlsson E, Parmley WW: Left ventricular volume from paired biplane two-dimensional echocardiography. *Circulation* **60**: 547, 1979
11. Starling MR, Crawford MH, Sorensen SG, Levi B, Richards KL, O'Rourke RA: Comparative accuracy of apical biplane cross-sectional echocardiography and gated equilibrium radionuclide angiography for estimating left ventricular size and performance. *Circulation* **63**: 5, 1981
12. Eaton LW, Maughan WL, Shoukas AA, Weiss JL: Accurate volume determination in the isolated ejecting canine left ventricle by two-dimensional echocardiography. *Circulation* **60**: 320, 1979
13. Silverman NH, Ports TA, Snider AR, Schiller NB, Carlsson E, Heilbron DC: Determination in left ventricular volume in children: echocardiographic and angiographic comparisons. *Circulation* **62**: 548, 1980
14. Folland ED, Parisi AF, Moynihan BS, Jones DR, Feldman CL, Tow DE: Assessment of left ventricular ejection fraction and volumes by real-time, two-dimensional echocardiography. *Circulation* **60**: 760, 1979
15. Geiser EA, Bove KE: Calculation of left ventricular mass and relative wall thickness. *Arch Pathol* **97**: 13, 1974
16. Wyatt HL, Heng K, Meerbaum S, Hestenes JD, Cobo JM, David-

- son R, Corday E: Cross-sectional echocardiography — analysis of mathematic models for quantifying mass of the left ventricle in dogs. *Circulation* **60**: 1104, 1979
17. Henry WL, Clark CE, Epstein SE: Asymmetric septal hypertrophy. *Circulation* **47**: 225, 1973
18. Schiller N, Skiöldebrand C, Schiller E, Mavroudis C, Silverman N, Rahimtoola S, Lipton M: In vivo assessment of left ventricular mass by two-dimensional echocardiography. *Circulation* **59** (suppl II): II-18, 1979 (abst)
19. Helak JW, Reichek N: Quantitation of human left ventricular mass and volume by two-dimensional echocardiography: in vitro anatomic validation. *Circulation* **63**: 1398, 1981
20. Wahr D, Wang Y, Skiöldebrand C, Schiller EJ, Lipton MJ, Schiller NB: Clinical quantitative echocardiography III. Left ventricular mass in a normal adult population. *Clin Res* **30**: 23A, 1982
21. Reiner L, Mazzoleni A, Rodriguez FL, Freudenthal RR: The weight of the human heart. *Arch Pathol* **68**: 58, 1959
22. Kennedy WJ, Baxley WA, Figley MM, Dodge HT, Blackmon JR: Quantitative angiography I: The normal left ventricle in man. *Circulation* **34**: 272, 1966
23. Reichek N, Helak J, Plappert T, St. John Sutton M, Weber KT: Anatomic validation of left ventricular mass estimates from clinical two-dimensional echocardiography: initial results. *Circulation* **67**: 348, 1983

Canine left ventricular mass estimation by two-dimensional echocardiography.

N B Schiller, C G Skiöldebrand, E J Schiller, C C Mavroudis, N H Silverman, S H Rahimtoola
and M J Lipton

Circulation. 1983;68:210-216

doi: 10.1161/01.CIR.68.1.210

Circulation is published by the American Heart Association, 7272 Greenville Avenue, Dallas, TX 75231

Copyright © 1983 American Heart Association, Inc. All rights reserved.

Print ISSN: 0009-7322. Online ISSN: 1524-4539

The online version of this article, along with updated information and services, is located on
the World Wide Web at:

<http://circ.ahajournals.org/content/68/1/210>

Permissions: Requests for permissions to reproduce figures, tables, or portions of articles originally published in *Circulation* can be obtained via RightsLink, a service of the Copyright Clearance Center, not the Editorial Office. Once the online version of the published article for which permission is being requested is located, click Request Permissions in the middle column of the Web page under Services. Further information about this process is available in the [Permissions and Rights Question and Answer](#) document.

Reprints: Information about reprints can be found online at:
<http://www.lww.com/reprints>

Subscriptions: Information about subscribing to *Circulation* is online at:
<http://circ.ahajournals.org/subscriptions/>